

# Flap tearing during lift-flap laser in situ keratomileusis retreatment

Miguel J. Maldonado, MD, PhD, José R. Juberías, MD, PhD, David P. Piñero, OD,  
Aurora Alvarez-Vidal, SD, Allan R. Rutzen, MD

A flap tear occurred during laser in situ keratomileusis (LASIK) retreatment using a flap-lifting technique in 1 eye of 2 patients 4 to 5 months after the primary procedure. In the first case, the tear occurred in a decentered, standard thickness flap (168  $\mu\text{m}$ ) in a location close to the corneal limbus and limbal vessels. In the second case, the tear occurred in a well-centered thin flap (116  $\mu\text{m}$ ) that involved a peripheral corneal pannus. The false track was identified early, and central extension of the tear was averted. After the flap was successfully dissected, retreatment was performed without further complications. This report suggests that flaps with margins near the limbus or a corneal pannus may be prone to an earlier and stronger healing process at the edge that may lead to a flap tear during LASIK retreatment. This may be of increasing importance because of the trend toward larger flap diameters.

*J Cataract Refract Surg* 2005; 31:2016–2018 © 2005 ASCRS and ESCRS

Residual refractive errors following laser in situ keratomileusis (LASIK) can be effectively corrected with retreatment.<sup>1–3</sup> Two methods for LASIK retreatment are available: lifting the original flap or recutting a new flap. Flap lifting can even be performed years after the original surgery but is most easily performed within the first 3 to 12 months because healing at the interface is not fully mature.<sup>1–3</sup>

In most cases, the flap can be easily lifted using a spatula or forceps.<sup>4</sup> A small risk for complications, such as epithelial ingrowth, and flap melting, has been reported after flap lifting.<sup>1,5</sup> We describe 2 cases of peripheral flap tearing during the flap lifting maneuver. To our knowledge, there are no previously published reports describing a flap tear in the periphery of the flap during LASIK enhancement.

Accepted for publication February 10, 2005.

From the Department of Ophthalmology (Maldonado, Juberías, Piñero, Alvarez-Vidal), University Clinic, University of Navarra, Pamplona, Spain, and Department of Ophthalmology (Rutzen), University of Maryland, Baltimore, Maryland, USA.

No author has a financial or proprietary interest in any material or method mentioned.

Supported in part by an unrestricted grant from Research to Prevent Blindness, New York, New York, USA.

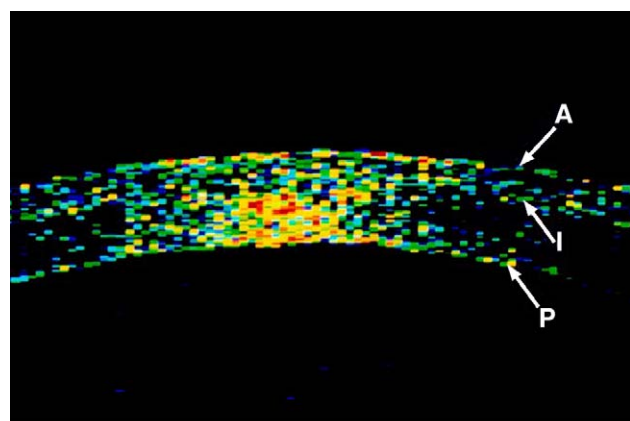
Reprint requests to Miguel J. Maldonado, MD, PhD, Departamento de Oftalmología, Clínica, Universitaria de Navarra, Avenida Pío XII 36, 31080 Pamplona, Spain. E-mail: [mjaldonad@unav.es](mailto:mjaldonad@unav.es).

## CASE REPORTS

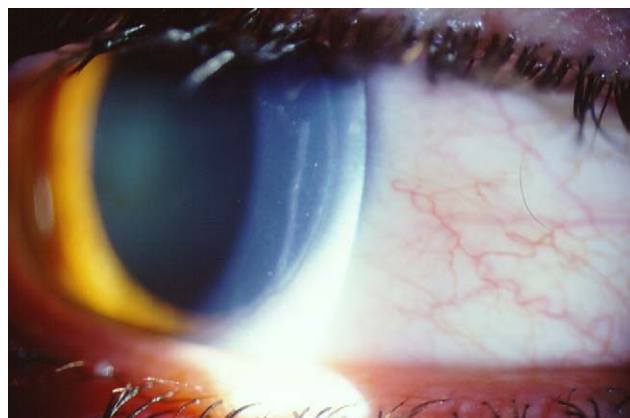### Case 1

A 22-year-old man with no history of contact lens wear had bilateral LASIK for myopia and astigmatism. The preoperative refractive error was  $-3.00 -1.00 \times 90$  in the right eye and  $-1.50$  in the left eye. The best spectacle-corrected visual acuity (BSCVA) was 20/20 in both eyes. The pupil diameter under scotopic conditions was 6.8 mm in both eyes. A Hansatome microkeratome (Chiron Vision) with a 180  $\mu\text{m}$  head and 9.5 mm ring was used to create a superior hinged flap. In the right eye, the flap was slightly decentered and the flap edge was close to the limbus at the nasal margin. The ablation was performed using the Technolas Keracor 217 excimer laser (Bausch & Lomb) at a 6.8 mm optical zone with 13.8 mm  $\times$  9.9 mm maximum outer treatment dimensions.

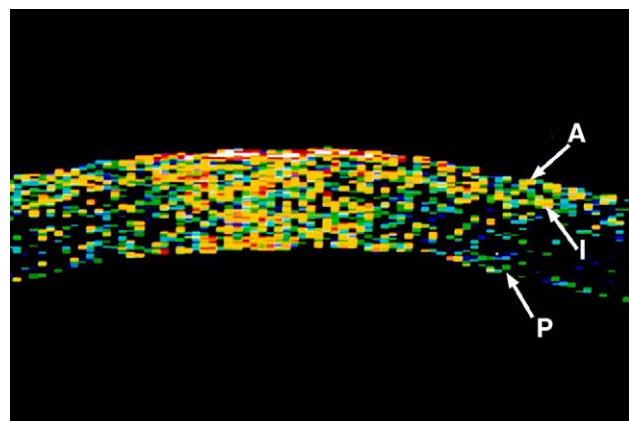
Five months after primary LASIK, the right eye had a residual refractive error of  $-0.50 -0.50 \times 5$ . The preenhancement flap thickness measured by optical coherence tomography was 168  $\mu\text{m}$  (Figure 1, A). A retreatment was performed using flap lifting. At the laser microscope, a toothless forceps was introduced under the temporal edge of the flap and advanced counterclockwise to dissect the flap margin. Resistance to dissection was found in the nasal margin of the flap, and an inadvertent tear in the flap started at the 5 o'clock position and extended to the 3 o'clock position (Figure 1, B). The flap capsulorhexis was discontinued, and a blunt spatula was used to dissect across the center of the flap to the nasal margin. At the completion of the maneuver, the main flap and torn segment were fully mobilized and reflected superiorly with an intact superior hinge. A small amount of bleeding arose from peripheral vessels in the nasal quadrant. The stromal bed was reablated, and the postoperative course was uneventful. The uncorrected visual acuity was 20/20 on the first day and over 2 years of follow-up.



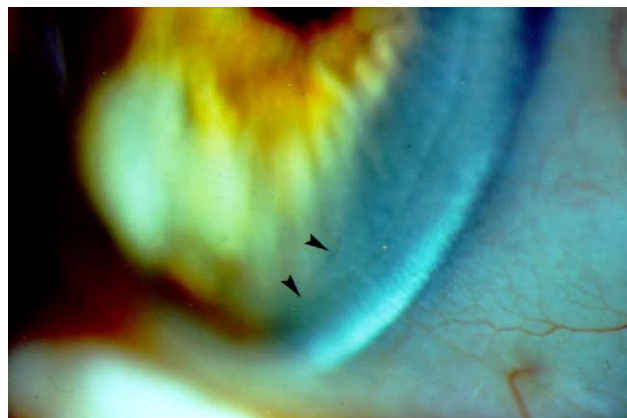A



B



A



B

**Figure 1.** Case 1. *A*: Optical coherence tomographic image reveals a 168  $\mu\text{m}$  thick corneal flap (A = anterior corneal surface; I = corneal flap interface; P = posterior corneal surface). *B*: Biomicroscopic examination 24 hours after tearing on the nasal edge of the flap during a lift-flap LASIK retreatment.

## Case 2

A 52-year-old woman with a 20-year history of soft contact lens wear had bilateral LASIK for myopia and astigmatism. Preoperative refractive error was  $-4.00 -1.00 \times 45$  in the right eye and  $-3.00 -2.00 \times 160$  in the left eye. The BSCVA was 20/25 in both eyes. Anterior segment biomicroscopy disclosed a peripheral corneal pannus extending 1.5 mm onto the cornea over 360 degrees of the limbus in both eyes. The pupil diameter under scotopic conditions was 6.3 mm in both eyes.

A Hansatome microkeratome with a 160  $\mu\text{m}$  head and 9.5 mm ring was used to create a well-centered, superior hinged flap in both eyes. The ablation was performed using the Technolas Keracor 217 excimer at a 6.3 mm optical zone with 13.3 mm  $\times$  9.4 mm maximum outer treatment dimensions.

Five months after primary LASIK, the right eye had a residual refractive error of  $-1.25$  diopters. The preenhancement flap thickness measured by optical coherence tomography was 116  $\mu\text{m}$  (Figure 2, A). A retreatment using flap lifting was performed. At the laser microscope, a toothless forceps was inserted at the temporal edge of the flap and used to dissect counterclockwise around

**Figure 2.** Case 2. *A*: Optical coherence tomographic image shows a 116  $\mu\text{m}$  thick corneal flap (A = anterior corneal surface; I = corneal flap interface; P = posterior corneal surface). *B*: Biomicroscopy examination 2 months after tearing on the nasal edge of the flap (arrowheads) during a lift-flap LASIK retreatment.

the flap margin. The flap margin strongly adhered to the bed, and additional resistance occurred in the inferior quadrant. A 1.0 mm tear began in the periphery at the 6 o'clock position, so the capsulorhexis was promptly halted (Figure 2, B). The forceps was then used to dissect the nasal margin of the flap and to lift the torn segment. Once the entire flap was successfully reflected along the superior hinge, the stromal bed was reablated. The postoperative course was uneventful, and the BSCVA was 20/25 over 1 year of follow-up after LASIK retreatment.

## DISCUSSION

Retreatment surgeries are useful to correct residual refractive errors in LASIK patients, and flap lifting is usually accomplished without complications.<sup>1-3</sup> In these cases, we describe 2 cases in which flap lifting<sup>4</sup> resulted in a peripheral flap tear. In the first case, the tear occurred in a flap of standard thickness in a location close to the corneal limbus and limbal vessels. In the second case, the tear occurred in

a thin, well-centered flap that involved a peripheral corneal pannus.

The proximity of the corneal limbus and corneal vessels may have played a role in the genesis of flap tears in both cases. Wound-healing response after LASIK has been reported to be stronger at the flap margin than at the interface.<sup>6</sup> Studies of cataract incision healing in cats have shown that limbal incisions heal more rapidly and show a stronger fibroblastic response than incisions in clear cornea.<sup>7,8</sup> The vigorous wound-healing response of the peripheral vascular cornea correlates with our difficulty dissecting the flap margin and the occurrence of flap tears in these patients.

Awareness of this potential complication of flap lifting may be increasingly important in the future. There is a trend toward larger flap diameters because of larger ablations zones for wavefront-guided treatments, patients with large pupils, and hyperopic ablations.<sup>9</sup> Larger flaps that encroach on the corneal limbus may lead to a greater risk for a flap tear during retreatment surgery.

Gressel and Belsole<sup>5</sup> reported a slightly different complication during LASIK retreatment in a patient who had previously had photorefractive keratectomy for myopia, followed by hyperopic LASIK retreatment. When flap lifting was attempted for a second retreatment, a central tear developed at the edge of the zone of corneal haze. They postulate that the corneal haze indicated an area of exuberant wound healing that resulted in strong flap adhesion to the bed and suggest that recutting a LASIK flap may be safer than flap lifting it in the presence of haze.

The timing of retreatment is another important factor in the strength of flap and may affect the risk for a flap tear. Retreatments for residual refractive errors following LASIK are usually performed at least 3 months after the initial procedure or once refractive stability is established. Our patients both had retreatment relatively early in their postoperative course, 4 or 5 months postoperatively, but still experienced the complication of a flap tear. Because flap adhesion increases over time, patients who are retreated later in their course may be at increased risk for a flap tear.

In addition, flap thickness may be an important factor influencing tearing. Thin flaps would be more easily torn during flap lifting than thick flaps, especially if strong wound healing has occurred. Using a technique that we previously described,<sup>10</sup> we measured flap thickness by optical coherence tomography in each case. The preenhancement flap thickness was normal (168  $\mu\text{m}$ ) in case 1, but thin (116  $\mu\text{m}$ ) in case 2.

To prevent a peripheral flap tear such as those described in this report, we suggest that the circular flap capsulorhexis technique should be modified when the flap edge involves vascularized areas such as the limbus or

contact lens–related pannus. In the area of vascularization, the surgeon should regrasp the flap edge with the forceps close to where the dissection left off to ensure maximal control of the peripheral, tangential dissection forces to achieve a circular flap lift without a tear. Moreover, this modification of technique should minimize the centripetal forces that would be created by a distant grasp and prevent the flap edge from tearing toward the center at the site of stronger peripheral adhesion.

Nevertheless, if excessive resistance is encountered, we recommend abandoning the flap capsulorhexis technique and dissecting across the center of the flap to the peripheral margin with a blunt spatula until the strongest flap-edge adhesion is overcome.

In conclusion, this report suggests that flaps with margins near the limbus or a corneal pannus, as found in many contact lens wearers, may be prone to an earlier and stronger healing process at the edge that may lead to a flap tear during LASIK retreatment. In addition, a thin flap may increase the risk for a flap tear. Refractive surgeons should therefore be aware of this potential complication and take measures to prevent it. In these cases, the flap should be lifted carefully with attention to the margin so that a flap tear can be recognized early and central extension can be avoided.

## REFERENCES

1. Pérez-Santonja JJ, Ayala MJ, Sakla HF, et al. Retreatment after laser in situ keratomileusis. *Ophthalmology* 1999; 106:21–28
2. Domniz Y, Comaish I, Lawless MA, et al. Recutting the cornea versus lifting the flap: comparison of two enhancement techniques following laser in situ keratomileusis. *J Refract Surg* 2001; 17:505–510
3. Febraro JL, Buzard KA, Friedlander MH. Reoperations after myopic laser in situ keratomileusis. *J Cataract Refract Surg* 2000; 26:41–48
4. Pérez-Santonja JJ, Medrano M, Ruiz-Moreno JM, et al. Circular flap-rhexis: a refinement technique for LASIK retreatment. *Arch Soc Esp Ophthalmol* 2001; 76:303–308
5. Gressel MG, Belsole VL. Laser in situ keratomileusis flap tear during lifting for enhancement in the presence of post-photorefractive keratectomy corneal haze. *J Cataract Refract Surg* 2004; 30:706–708
6. Alió JL, Pérez-Santonja JJ, Tervo T, et al. Postoperative inflammation, microbial complications, and wound healing following laser in situ keratomileusis. *J Refract Surg* 2000; 16:523–538
7. Barba KR, Samy A, Lai C, et al. Effect of topical anti-inflammatory drugs on corneal and limbal wound healing. *J Cataract Refract Surg* 2000; 26:893–897
8. Ernest P, Tipperman R, Eagle R, et al. Is there a difference in incision healing based on location? *J Cataract Refract Surg* 1998; 24:482–486
9. Carones F, Vigo L, Scandola E. Laser in situ keratomileusis for hyperopia and hyperopic and mixed astigmatism with LADARVision using 7 to 10-mm ablation diameters. *J Refract Surg* 2003; 19:548–554
10. Maldonado MJ, Ruiz-Oblitas L, Munuera JM, et al. Optical coherence tomography evaluation of the corneal cap and stromal bed features after laser in situ keratomileusis for high myopia and astigmatism. *Ophthalmology* 2000; 107:81–88